



PRESENTING CLINICAL SIGNS

History: Grade 1/6 murmur. BNP 119. Pre-dental evaluation.

DATE

12/20/22

ECHOCARDIOGRAPHIC FINDINGS

2D, M-mode, and Doppler study.

PERFORMED BY:

Kim Liedberg

INTERPRETED BY

Keith Blass, DVM,
MS, DACVIM
(Cardiology)

There is mild left atrial dilation. The mitral valve is normal. Left ventricular wall thickness is normal. Left ventricular internal dimensions are normal. Left ventricular systolic function is hyperdynamic. The aorta and aortic valve are normal. Right atrial and right ventricular dimensions are normal. The tricuspid valve appears normal, though mild tricuspid regurgitation is present. TR velocity does not suggest the presence of pulmonary hypertension. The pulmonary artery and pulmonic valve are normal. No shunting lesions are visualized. No pericardial effusion or cardiac masses are seen.

LA - 13.3 mm
LA/Ao 1.20
IVSd - 4.7 mm
LVPWd - 4.3 mm
LVIDd - 12.3 mm
LVIDs - 5.1 mm
FS - 58.5%
LVOT - 0.95 m/s
RVOT - 0.90 m/s
TR - 2.11 m/s

PATIENT

Stormy Hufford

SPECIES

Feline

ASSESSMENT/RECOMMENDATIONS

BREED

This examination demonstrates mild regurgitation of blood across Stormy's tricuspid valve. The hemodynamic effects of the regurgitation are also mild, and Stormy's current risk for the development of clinical signs secondary to it is low.

DSH

Stormy's cardiovascular risk for general anesthesia is low based on this exam, though I still recommend avoiding the use of alpha-2 agonists in the anesthetic protocol and reducing the IV fluid rate by 25% as precautions. If possible, monitoring of heart rhythm, blood pressure, and pulse oximetry are recommended during the procedure.

SEX

MN

No therapy is recommended based on this exam.

AGE

A recheck echocardiogram is recommended in 9-12 months, sooner if new clinical signs compatible with cardiac dysfunction develop.

12 y

WEIGHT

8.35 lb

HOSPITAL NAME

SVS Imaging WI

REFERRING VET

Dr. Brown



DATE

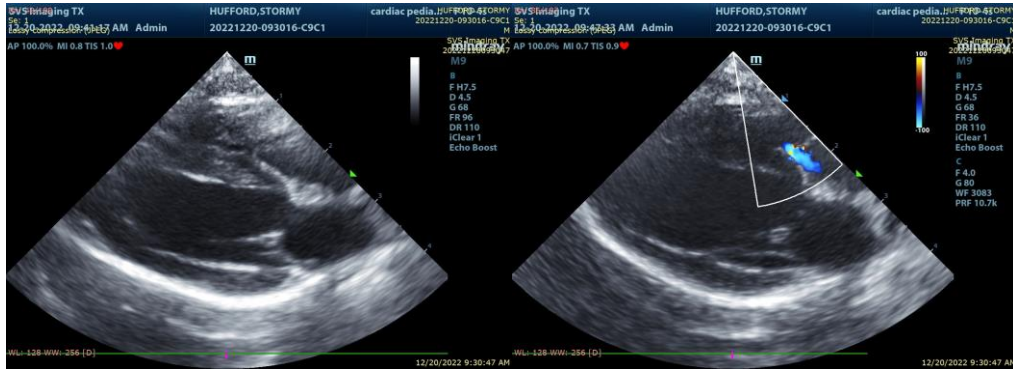
12/20/22

PERFORMED BY:

Kim Liedberg

INTERPRETED BY

Keith Blass, DVM,
MS, DACVIM
(Cardiology)



The information and recommendations provided are based on the images presented by the referring veterinarian. No evaluation can be communicated regarding pathology that was not visible in the image/video clips provided.

Thank you for this referral. If the clinical or image interpretation does not parallel your findings or if I can be of any further assistance please contact me.

PATIENT

Stormy Hufford

Keith Blass, DVM, MS, DACVIM (Cardiology)
KeithBlass@gmail.com
631-804-5754

SPECIES

Feline

BREED

DSH

SEX

MN

AGE

12 y

WEIGHT

8.35 lb

HOSPITAL NAME

SVS Imaging WI

REFERRING VET

Dr. Brown